



Metastatic pancreatic adenocarcinoma to the scrotum

Pankreas adenokarsinomunun skrotal metastazı

Michael J. Amirian, Alex M. Arnouk, Kelly A. Healy

ABSTRACT

Metastatic cancer to the scrotum is a rare occurrence. We describe the first case of cutaneous scrotal lesions consistent with metastatic pancreatic adenocarcinoma. A brief discussion including epidemiologic factors and clinical presentation is presented.

Keywords: Adenocarcinoma; scrotal cellulitis; scrotal metastases; scrotal swelling.

ÖZ

Skrotumun metastatik kanseri nadiren görülür. Metastatik pankreas adenokarsinomuyla uyumlu skrotum derisi lezyonları saptanan ilk olguyu tanımlıyoruz. Epidemiyolojik faktörler ve klinik tablonun kısa bir tartışması da sunulmaktadır.

Anahtar Kelimeler: Adenokarsinom; skrotal selülit; skrotal metastazlar; skrotal ödem.

Introduction

There are a variety of dermatologic conditions that can present as scrotal pathology, and under rare circumstances, solid organs can metastasize to the scrotum. While cutaneous metastases from primary malignancies are not uncommon, metastasis to the scrotum is a seldom seen. In a retrospective study of 4020 patients with metastatic carcinoma^[1] the overall incidence of cutaneous metastasis was 10%, of whom only one patient developed metastasis to the scrotum (0.02%).

A recent review of cutaneous scrotal metastases by Hoyt et al.^[2] describes the 29 reported cases of solid organ visceral malignancies with metastasis to the scrotum. Of those with a primary malignancy of gastrointestinal origin, none were described from the pancreas. To our knowledge, this may be the first reported case of primary pancreatic adenocarcinoma with cutaneous metastasis to the scrotum.

Case presentation

A 65-year old male with a history of tobacco abuse, (25-pack-years), heavy alcohol (3-4

days/week) use, and remote intravenous drug use presented to the emergency room with a one month history of progressive scrotal pain, swelling, and drainage of fluid from the skin, which was concerning for scrotal cellulitis. He also complained of fatigue, fevers, chills, nausea, decreased oral intake, and weight loss. On physical exam, the patient was afebrile and hemodynamically stable. His scrotum was edematous with areas of induration, erythema, and drainage of tan clear fluid. Additionally, two 1 cm superficial ulcerations were noted on the dorsal surface of the penile mid-shaft and were tender to palpation. No overt purulence, fluctance, or crepitus were identified. There was no palpable inguinal lymphadenopathy.

Workup for the scrotal swelling included computed tomography (CT) of the chest, abdomen, and pelvis, which showed no scrotal pathology. This demonstrated an incidental 4.7 x 2.5 cm distal pancreatic body-tail mass, T12 vertebral body lesion, and innumerable pulmonary nodules consistent with metastasis. Metastatic pancreatic adenocarcinoma was confirmed through pathological specimens obtained via trans-bronchial and ERCP-guided percutaneous fine needle pancreatic biopsies. The patient was treated with in-

Department of Urology,
Thomas Jefferson University
Hospital, Philadelphia, USA

Submitted:
06.05.2016

Accepted:
13.07.2016

Available Online Date:
03.05.2017

Correspondence:
Michael J. Amirian
E-mail:
michael.amirian@jefferson.edu

©Copyright 2017 by Turkish
Association of Urology

Available online at
www.turkishjournalofurology.com

travenous antibiotics for presumed scrotal cellulitis and underwent a negative work-up for sexually transmitted diseases including syphilis, HIV, hepatitis B, gonorrhea, and chlamydia, with the exception of newly diagnosed hepatitis C. He also received a course of acyclovir to treat the remote possibility of herpetic etiology.

Following this, the patient was given a trial of chemotherapy (mFOLFOX6 regimen consisting of oxaliplatin, leucovorin, fluorouracil), which he poorly tolerated. He ultimately elected palliative care under home hospice. Three months after his initial diagnosis of pancreatic cancer, the patient reversed his decision for hospice and presented to our medical center's oncologist seeking a second opinion.

At his initial medical oncology visit, he was directly sent to the emergency room for evaluation of his scrotal wound. During this examination (Figure 1), the patient's genitourinary region was now with a more purulent exudative discharge. Furthermore, the patient reported symptoms of increasing pain and swelling. Urology was consulted and recommended punch biopsies of the scrotum and groin. Both histopathology and immunochemistry were consistent with pancreatic adenocarcinoma (Figure 2). He was not deemed a candidate for chemotherapy given his extremely poor functional status.

Discussion

This case describes a patient who presented with cutaneous lesions on his scrotum and was incidentally found to have metastatic pancreatic cancer. Of the 29 cases of scrotal metastasis reported^[2], they most commonly (13 of 29) originated from the urogenital tract (encompassing origins in the prostate, bladder, kidney, and urethra). This is consistent with reports that cutaneous manifestations most frequently are reported at locations in the vicinity of the primary tumor.^[1] The gastrointestinal tract (encompassing origins in the colon/rectum and stomach) was also shown to be the second most common organ system responsible (11 of 29), and to our knowledge, none of those cases reported have been described as pancreatic in origin.

While symptoms suggestive of his diagnosis were apparent at the time of his admission, including unexplained weight loss and fatigue, his scrotal lesions were his initial presenting complaint, leading to the discovery of his malignancy. Interestingly, in 20% of the patients described with scrotal metastases (6 of 29), the scrotal cutaneous lesions were the initial sign of internal malignancy or were identified within one month of diagnosis.^[2] Also, in reviewing 22 cases of cutaneous metastatic pancreatic cancer, in 11 of the cases, the metastatic lesions to the skin were the first symptoms of pancreatic cancer.^[1]

The incidence of cutaneous metastatic manifestations of pancreatic cancer has been estimated at 2.0%, and the most fre-

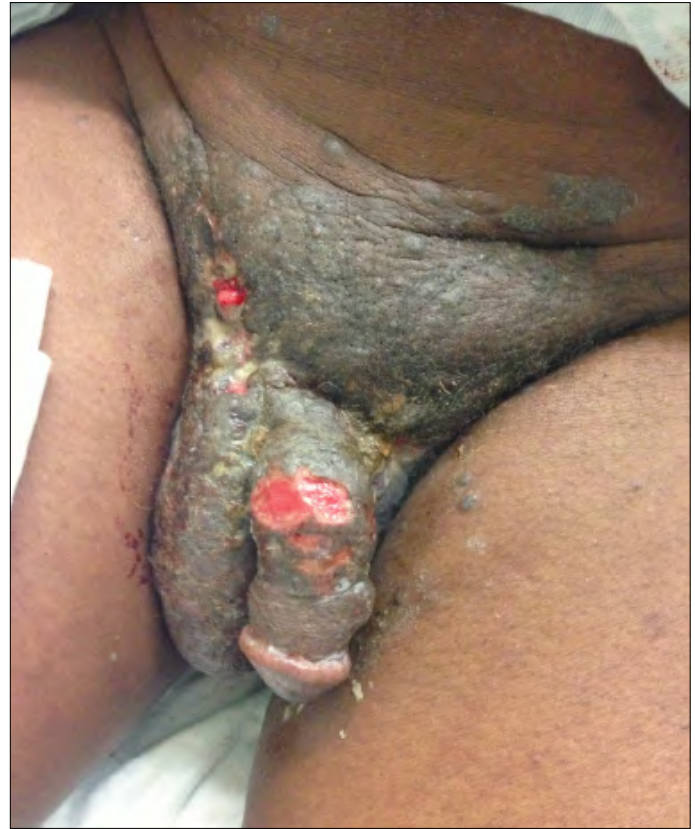

Figure 1. Cutaneous manifestation of pancreatic adenocarcinoma metastases to the scrotum. Note generalized induration and edema in scrotal region with areas of exudate and superficial ulceration. While warm and tender to palpation, no crepitus or fluctuation was appreciated. Two areas of superficial ulceration are seen in mid-shaft of the penis, stable from initial presentation four months prior

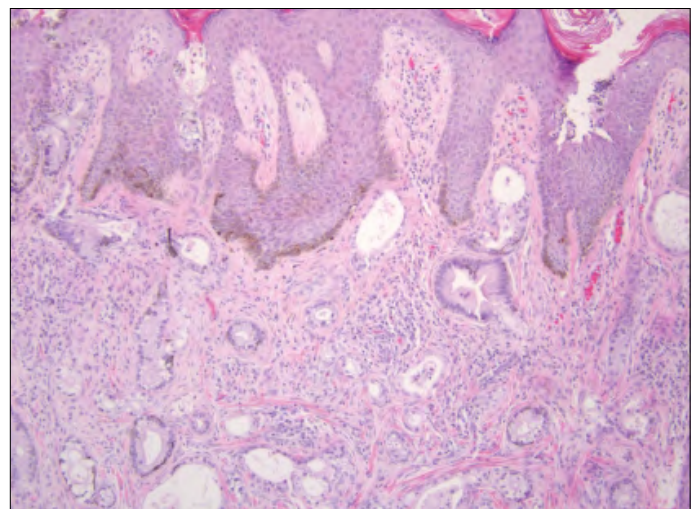


Figure 2. 100x H&E stain showing metastatic adenocarcinoma to the skin

quent site of metastasis was the umbilicus, known as Sister Mary Joseph's nodule.^[1] Again, these reports substantiate that metastases are often near the site of the primary tumor. It is not uncommon, however, for distal metastases; 39% of patients noted to have cutaneous metastases in Lookingbill et al.'s study^[3] were found at distal sites. Interestingly, local metastases have also been described at scars of past surgical incision sites.^[4] While the patient did have surgical scars associated with his prior laparoscopic prostatectomy and bilateral herniorrhaphies, no cutaneous manifestations were found along these healed scars. One can speculate that adhesions associated with these previous incisions may have somewhat assisted in tumor travel to the scrotum.

Although incompletely understood, the biologic basis of tumor metastasis generally involves invasion of a blood or lymphatic vessel, detachment from primary site, circulation in the blood, and reattachment at a distant site with proliferation.^[1] While non-umbilical cutaneous metastases are rare in pancreatic cancer, distant spread as demonstrated by our patient and others, exhibit that pancreatic carcinoma can reach other cutaneous tissues via blood or the lymphatic system.

Cutaneous nodules were found to be the most frequent manifestation (19 of 29 men) of scrotal metastases.^[2] Our patient presented with generalized induration, highlighting the morphological variability of metastatic cutaneous lesions. Our patient's generalize induration and edema mimics that of an inflammatory reaction. Inflammatory skin metastases, sometimes mimicking cellulitis, are most frequently caused by breast cancer.^[3] Furthermore, histologic pathology of punch biopsies of the scrotum in our patient revealed metastatic adenocarcinoma consistent with the primary source. As per prior studies^[2,3], histological findings most frequently revealed adenocarcinoma at site of cutaneous metastasis. This may be suggestive that adenocarcinomatous lesions have a more favorable predilection in travel to skin.

Skin metastases represent a grave prognostic sign^[1], and most patients survive less than a year after appearance of skin lesions. Most recent data generally indicates survival is typically four months or less after appearance of cutaneous metastases to the scrotum.^[5] Of the 42 patients with cutaneous metastases from pancreatic cancer that Horino et al.^[1] analyzed, the only prognostic factor was receiving chemotherapy or chemoradiotherapy. To our knowledge, the patient described is still alive at time that this report.

Informed Consent: Written informed consent was obtained from patient who participated in this study.

Peer-review: Externally peer-reviewed.

Author Contributions: Concept - K.A.H.; Design - K.A.H.; Supervision - K.A.H.; Materials - A.A.; Data Collection and/or Processing - A.A.; Analysis and/or Interpretation - M.J.A.; Literature Search - A.A.; Writing Manuscript - M.J.A., A.A.; Critical Review - K.A.H.

Conflict of Interest: No conflict of interest was declared by the authors.

Financial Disclosure: The authors declared that this study has received no financial support.

Hasta Onamı: Yazılı hasta onamı bu çalışmaya katılan hastadan alınmıştır.

Hakem Değerlendirmesi: Dış bağımsız.

Yazar Katkıları: Fikir - K.A.H.; Tasarım - K.A.H.; Denetleme - K.A.H.; Malzemeler - A.A.; Veri Toplanması ve/veya İşlemesi - A.A.; Analiz ve/veya Yorum - M.J.A.; Literatür Taraması - A.A.; Yazıyı Yazan - M.J.A., A.A.; Eleştirel İnceleme - K.A.H.

Çıkar Çatışması: Yazarlar çıkar çatışması bildirmemişlerdir.

Finansal Destek: Yazarlar bu çalışma için finansal destek almadıklarını beyan etmişlerdir.

References

1. Horino K, Takamori H, Ikuta Y, Nakahara O, Chikamoto A, Ishiko T, et al. Cutaneous metastases secondary to pancreatic cancer. *World J Gastrointest Oncol* 2012;4:176-80. [\[CrossRef\]](#)
2. Hoyt BS, Cohen PR. Cutaneous scrotal metastasis: origins and clinical characteristics of visceral malignancies that metastasize to the scrotum. *Int J Dermatol* 2013;52:398-403. [\[CrossRef\]](#)
3. Lookingbill DP, Spangler N, Helm KF. Cutaneous metastases in patients with metastatic carcinoma: a retrospective study of 4020 patients. *J Am Acad Dermatol* 1993;29:228-36. [\[CrossRef\]](#)
4. Pontinen T, Melin A, Varadi G, Khanmoradi K, Chewaproug D, Kung SC, et al. Cutaneous metastasis of pancreatic adenocarcinoma after kidney transplant: a case report and review of the literature. *Exp Clin Transplant* 2010;8:273-6.
5. Miyahara M, Hamanaka Y, Kawabata A, Sato Y, Tanaka A, Yamamoto A, et al. Cutaneous metastases from pancreatic cancer. *Int J Pancreatol* 1996;20:127-30.